


PATIENT

Royce Beck

PRESENTING CLINICAL SIGNS

History: Severe heart murmur. Asymptomatic.

SPECIES

Canine

BREED

French Bulldog

SEX

Female

AGE

12 weeks

WEIGHT

5.8lbs

INTERPRETED BY

 Maggie Machen Lamy,
 DVM, DACVIM
 (Cardiology)

IMAGING PERFORMED BY

Lindsey Daniel, DVM

HOSPITAL NAME

 Midland Animal
 Hospital

REFERRING VET

Dr. Tatum

ECHOCARDIOGRAM FINDINGS

2D, m-mode, color flow and doppler imaging is available. Normal mitral valve leaflets with no obvious prolapse into the left atrial lumen. No obvious mitral regurgitation. Normal left atrial dimension. Normal LV diameter with normal myocardial function. The LV wall appears normal. The tricuspid valve appears normal. No TR seen. Moderate right atrial dilation. Moderate right ventricular enlargement/hypertrophy indicative of pressure overload. Pulmonic outflow velocities are severely elevated at the level of the valve. The pulmonic valve leaflets cannot be visualized extensively, however there is a thick ridge of tissue in the region consistent with stenosis. A sub/supravulvar component cannot be ruled out. Mild pulmonic insufficiency. There is significant post-stenotic dilation of the main pulmonary artery. The aortic valve appears to have normal morphology and mobility. No obvious cardiac shunts are present. No pericardial or pleural effusion noted.

CARDIAC CHART

CANINE CARDIAC PARAMETERS	MR VMAX (m/s)	TR VMAX (m/s)	LA/AO (Boon method)	LA/AO (Heart Base; Swe)	FS (%)	EF (%)	EPSS (cm)
NORMAL PARAMETER	4.5-5.5	<2.7	1.3	<1.6	28-40	40-100	<0.6
PATIENT	NA	NA	1.0	1.1	48	84	NM
CANINE CARDIAC PARAMETERS	HR (BPM)	AV VMAX (m/s)	PV MAX (m/s)	BODY WEIGHT (kg)	LA 2D short axis Base view (cm)	LVIDd Avg; 2D and m-mode short axis (cm)	LVIDs Avg; 2D and m-mode short axis (cm)
NORMAL PARAMETER	50-100	0.7-1.7	0.7-1.6	BELOW	BELOW	BELOW	BELOW
PATIENT	150	1.4	5.5	2.6	1.4	1.3	0.7
*Normal chamber parameters expressed as a mean value (SD)				3	1.27 (5.3)	2.46 (2.46)	1.36 (5.5)
BODY WEIGHT DEPENDENT PARAMETERS				5	1.40 (4.5)	2.74 (5.2)	1.60 (4.7)
*Note: All measurements based upon multi-modal images and methods. An average value is reported.				10	1.50 (3.8)	3.27 (3.5)	2.06 (3.1)
				15	1.83 (2.0)	3.71 (2.4)	2.43 (2.1)
				20	2.02 (1.9)	4.14 (2.2)	2.80 (2.0)
				25	2.18 (2.4)	4.48 (2.9)	3.10 (2.5)
				30	2.33 (3.3)	4.83 (3.9)	3.39 (3.4)
				35	2.48 (4.3)	5.17 (5.0)	3.69 (4.5)
				40	2.62 (5.2)	5.48 (6.1)	3.96 (5.4)
				50	2.88 (7.1)	6.07 (8.3)	4.46 (7.4)

INTERPRETATION OF THE FINDINGS & FURTHER RECOMMENDATIONS

The cause of the murmur is severe pulmonic stenosis. The degree of obstruction is severe based upon the velocity/pressure gradient across the pulmonic valve and the secondary hypertrophy and remodeling of the right ventricle. The exact location of the stenosis is suspected to be valvular; however, due to the degree of abnormality a sub/supravulvar component cannot be ruled out. There is significant RA/RV dilation, indicating significant pressure overload and the risk for CHF will be elevated going forward. No other congenital abnormalities were visualized, however small shunts or defects can be easily missed.

INVOICE

27269

DATE

11/3/22



PATIENT

Royce Beck

Referral for consultation and balloon valvuloplasty should be considered in this patient as the gold standard therapeutic option for this condition and may improve long term outcome and delay onset of clinical signs (including exertional syncope and right-sided congestive heart failure). It should be mentioned that bulldog breeds are predisposed to an abnormal coronary artery pattern that can further obstruct flow through the vessel and would limit surgical options if present. An angiogram must be performed to rule out this possibility prior to surgery.

SPECIES

Canine

BREED

French Bulldog

If surgery is not elected, this patient's condition will likely limit lifespan, with many severe PS cases developing CHF by mid-life (particularly with this degree of changes at 3mo old). Medical management with atenolol is recommended to decrease heart rate and lessen the obstruction as below. I don't typically institute this medication at such a young age; however, this should not be instituted until the patient is at least 4 months of age. Monitor for development of associated clinical signs (collapse, abdominal distention, cough, labored breathing). Mild exercise restriction is advised.

SEX

Female

AGE

12 weeks

From a legal standpoint, reassessment by an Attending Cardiologist may be useful depending on the client's course of action going forward. PS is a known genetic issue in this particular breed and the breeding line should be reassessed.

WEIGHT

5.8lbs

Anesthetic risk is mild to moderate at this time. **Avoid heart rate stimulating drugs such as atropine or glycopyrrolate unless absolutely necessary.** Avoid vasodilators such as acepromazine. Mild IV fluid restriction is advised. Cardiac protective drug choices (opioid/benzodiazepine premedication, propofol or alfaxalone induction, isoflurane gas) are recommended. Pre-oxygenate for 5-10 minutes prior to induction and recover in O₂ if possible. Monitor for arrhythmias, hypotension, and hypoxia both intra and post-operatively and intervene as necessary.

INTERPRETED BY

Maggie Machen Lamy,
DVM, DACVIM
(Cardiology)

PLAN

Institute atenolol to effect: 25mg tabs, ¼ tab PO SID to start (up-titrate to desired effect). Goal is to suppress heart rate <120bpm even with stress/activity. Baseline chest radiographs and ECG are recommended. Referral for angiogram/balloon valvuloplasty ASAP if desired.

IMAGING PERFORMED BY

Lindsey Daniel, DVM

If surgery is declined, recommend recheck echocardiogram in 6 months (or when full stature) to assess for progression, response to medication.

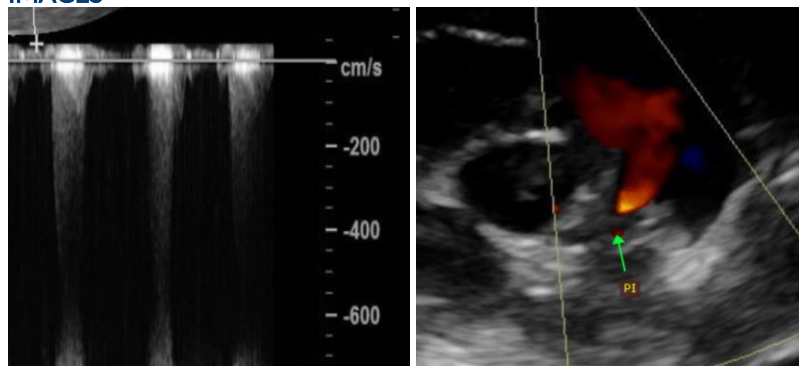
HOSPITAL NAME

Midland Animal
Hospital

IMAGES

REFERRING VET

Dr. Tatum



INVOICE

27269

DATE

11/3/22



PATIENT

Royce Beck

SPECIES

Canine

BREED

French Bulldog

SEX

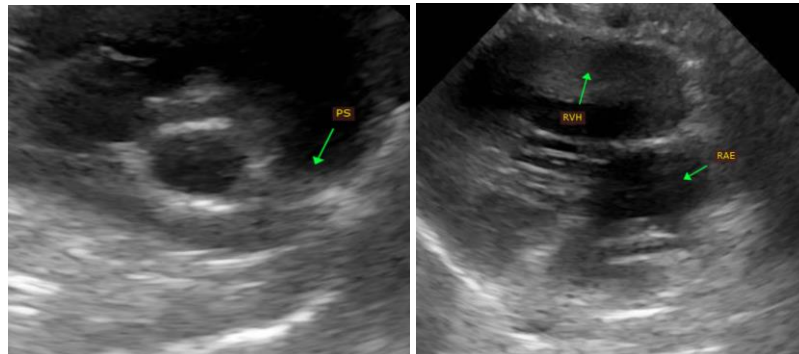
Female

AGE

12 weeks

WEIGHT

5.8lbs



The information and recommendations provided are based on the images presented by the referring veterinarian. No evaluation can be communicated regarding pathology that was not visible in the image/video clips provided.

Thank you for this referral. This report was generated using transcription software, and minor dictation errors may be present. If the clinical or image interpretation does not parallel your findings or if I can be of any further assistance, please contact me.

Maggie Machen Lamy, DVM
Diplomate of the American College of Veterinary Internal Medicine (Cardiology)
info@sonopath.com

INTERPRETED BY

Maggie Machen Lamy,
DVM, DACVIM
(Cardiology)

**IMAGING
PERFORMED BY**

Lindsey Daniel, DVM

HOSPITAL NAME

Midland Animal
Hospital

REFERRING VET

Dr. Tatum

INVOICE

27269

DATE

11/3/22